



RESEARCH ARTICLE

OSTEOGENESIS IMPERFECTA IN DENTISTRY

^{1,*}Sidqui, M. and ²Chafi, I.

¹Department of Biology- Faculty of Medicine of Casablanca -University of Hassan II. Morocco, Chief of service of Emergency. Professor of Biochemistry-Chu Ibn Rochd of Casablanca, Morocco

²A PhD student of Centre of Doctoral study in health science-Doctoral training in genetics and molecular pathology-Faculty of Medicine and Pharmacy of Casablanca-Hassan II University of Casablanca, Morocco

ARTICLE INFO

Article History:

Received 06th September, 2018
Received in revised form
17th October, 2018
Accepted 26th November, 2018
Published online 20th December, 2018

ABSTRACT

In light of this review of the literature, the objectives of this thesis are first set osteogenesis imperfecta. A description of the diagnostic criteria allow us to clearly classify the disease. Then we try to understand the genetic process to analyze the mechanisms responsible for the disease. Thereafter, we will detail the different clinical manifestations associated with osteogenesis imperfecta. Finally, we will review the management illustrated by case reports and therapeutic approach adapted.

Keywords:

Osteogenesis Imperfecta,
Dentistry, Tooth, Bone.

Copyright © 2018, Sidqui and Chafi. This is an open access article distributed under the Creative Commons Attribution License, which permits unrestricted use, distribution and reproduction in any medium, provided the original work is properly cited.

INTRODUCTION

Osteogenesis imperfecta (OI) is a heterogeneous group of syndromes characterized by high bone fragility resulting in skeletal deformities and multiple fractures for minimal trauma. The prevalence is currently estimated at 1/20,000 births. This disease, long known as "glass bone disease", is due to an abnormality in the production of type I collagen, which may be qualitative or quantitative. This results in a heterogeneous group of diseases ranging from lethal form at birth to benign forms and / or discovered forms in adulthood.

Definition of Osteogenesis Imperfecta:

Osteogenesis Imperfecta (OI) is one of the few dominant congenital diseases with a high rate of neo mutations. It is a complex and heterogeneous set of genetic diseases that mainly affect mineralized tissues, ie bones and teeth. Its clinical spectrum ranges from intrauterine death to a not very apparent phenotype, including osteopenia, multiple fractures and skeletal malformations (Ackerman, 1969).

Epidemiology: OI occurs around the world without distinction between the sexes. It is estimated that about 25,000 to 50,000 people are living with the disease in the United States.

*Corresponding author: Sidqui, M.,

Department of Biology- Faculty of Medicine of Casablanca -University of Hassan II. Morocco, Chief of service of Emergency. Professor of Biochemistry-Chu Ibn Rochd of Casablanca, Morocco.

A case of OI occurs in 10,000 live births, but the incidence around the world is highly variable. In Great Britain, 3400 cases have been reported. While in Denmark, the point prevalence at birth was estimated at 21.8 per 100,000 and the prevalence in the population was equal to 10.6 per 100,000 inhabitants. The database of the Latin American Collaborative Congenital Malformation Study (ECLAMC) between 1978 and 1983 showed that the OI prevalence rate was 0.4 per 10,000 births (American Academy of Pediatric Dentistry, 2013). In France, 3,000 to 6,000 people would be affected, a prevalence of 1 in 10,000 to 20,000 people (Barsh, 1981).

Classification of sillence: On the basis of the heterogeneity of the phenotypic manifestations and the mode of transmission of the disease, Sillence proposed in 1981 a classification of the OI into four major clinical phenotypes (Ackerman, 1969). Currently, only the classification of Sillence is allowed in the International literature (Aubry, 2004).

Osteogenesis imperfecta type I: Bone fragility is not severe: the first fractures occur at the age of walking, their annual frequency is less than two and may decrease after puberty. Growth is normal or slightly below normal. On the X-ray of the skull, Wormian bones are abnormally high in number. The bluish staining of the sclera of the eye is observed in 80% of subjects. Joint hyperlaxity is common and dentinogenesis imperfecta (DI) is present in one in four subjects. While forty percent of adults are deaf (Barsh, 1981).

Osteogenesis imperfecta type II: Osteogenesis imperfecta type II is the most severe form, often diagnosed prenatally. Newborns die of respiratory insufficiency: the thorax is very small, the ribs short and broad with a rosary aspect on X-ray. The long bones are very deformed and very short. The bones of the skull, clinically soft, are very little visible on x-rays because they are not very mineralized (Barsh, 1981).

Osteogenesis imperfecta type III: Osteogenesis imperfecta type III is the most severe form compatible with survival. These patients, very small, have a triangular face (macrocephaly, small chin and facial mass). Sclerotics, greyish in infants, may become lighter with time. The skeletal abnormalities are very severe: frequent pre- and postnatal fractures, long bones are very deformed and short, severe disorders of spinal statics in kyphosis and / or scoliosis by osteoporotic collapse of the vertebral body, as well as thoracic deformities. Trunk involvement is the cause of severe restrictive respiratory failure (Barsh, 1981).

Osteogenesis imperfecta type IV: Osteogenesis imperfecta type IV represents a very heterogeneous group of patients who do not belong to the first 3 groups. The range of clinical forms is wide. Sixty percent of patients have DI (Barsh, 1981). These patients suffer from periodic fractures, different degrees of deformity of the long bones and the spine, but a sclera that appears normal. It may appear blue at birth but fades during childhood.

Biochemical and molecular mechanisms of osteogenesis imperfecta: Biochemical and molecular genetic studies have shown that the majority of individuals (> 90%) affected by OI types I to IV have expressed mutations either in the COL1A1 or COL1A2 genes that encode procollagen type I chains, major structural protein of bone, skin and tendons. The underlying genetic defect of types V and VI of OI remains to be elucidated, as it does not seem to be associated with mutations of collagen type I as it was proven in other types of OI (Doyle, 1998). Amino acid sequencing of peptide fragments and then positional cloning and sequencing of complementary DNA and genomic DNA completely transformed in early 1990 our understanding of the pathogenesis of 85% of patients. It can be generalized and said that type I of OI is caused by mutations that are non-sense mutations, indels that result in reading or splicing mutations. In fact, splice mutations account for approximately one-third of mutations in patients with type I of OI, while nonsense mutations and mutations in the reading frame are responsible for the rest which is 1/3. However, in 15% of cases no abnormalities were detected in coding helix regions of COL1A1 and COL1A2. Virtually no mutations in the type I collagen gene have been described in the case of autosomal recessive disorder. At the same time, the advances made in collagen protein investigation technologies and in the molecular mechanisms of DNA have provided a precise description of the heterogeneity of the OI (Emrich, 1965).

Repercussions of the osteogenesis imperfecta in dentistry

Dentinogenesis imperfecta

Description and frequency: Dental abnormalities associated with osteogenesis imperfecta (OI) are known as dentinogenesis imperfecta (DI). Due to obvious clinical and radiographic similarities, DI also refers to an inherited disorder isolated from the development of dentin.

The classification of Shields et al. (1973) distinguishes type I, DI associated with OI, and types II (hereditary opalescent dentin) and III (Brandywine type), DI isolated. These two forms of ID, associated with OI or isolated, indicate different genetic abnormalities. The name DI should be reserved for isolated hereditary disorders type II and III. It has been proposed to refer to OI-related dental abnormalities, OI-associated dentinal dysplasia (Jorgenson, 1989) or O-associated opalescent teeth (Neville et al., 1995). The classification of OI, commonly used, into four major clinical phenotypes, is that of Silence. Types I and IV are subdivided into subtypes A (without DI) and B (with DI). DI is constant in type III. The prevalence of DI varies by author. It is, in mixed dentition, 52% for type I, 82% for type III and 54% for type IV (Vetter et al., 1992). The prevalence of permanent tooth DI of patients with Type III and IV OI is 36% and 65%, respectively (O'Connell and Marini, 1999). The severity of DI varies with dental development. It is more marked on temporary teeth than on permanent teeth. The clearest clinical sign is a change in hue from blue-gray to yellow-brown, often associated with abnormal translucency. The crowns enamel assigned to a hardness and a normal external appearance. It breaks down pathologically leaving the underlying dentin unprotected. This one is quickly abraded. The rate of wear of the temporary teeth is greatly increased when the color of the crowns is yellow-brown. On X-rays can be observed the following characteristic features: bulbous crowns, cervical constriction, short roots and sometimes transparent apical ray images. The pulp chambers are gradually filled, during or shortly after the eruption, by pulp stones or pathological dentin. Sometimes they remain abnormally wide. Exclusion of an DI on clinical and radiographic criteria alone may lead to errors and underestimations of its frequency. The abnormalities of the milk teeth are sometimes so slight that they can only be revealed by histological or ultra-structural observations. The literature reports a case where the diagnosis of DI preceded that of OI (Bonaféa et al., 2013)

Symptoms and Evolution

Color and tint of teeth: Among the most prominent dental abnormalities in patients with OI is the abnormal color of the apparent dentin through the enamel (Glorieux, 1998) Dentin, hypo mineralized, is darker than normal and appears clearly under the enamel. The dentin usually gives the teeth an opalescent appearance, more or less translucent, and a amber color more or less dark. Whitish opacities of the enamel are sometimes observed (Glorieux, 2007). The color can vary from light gray to dark gray with a variant of yellow hue. When the gray color is dominant, the tooth seems more translucent and deserves the term opalescent. A yellow tinge exists when the pulp becomes completely obliterated and the tooth loses its luminosity. Different pigments, including blood pigments, can also be responsible for different dental shades.

Lindau and Coll, (1999) used different biological techniques to investigate dentin morphology in OI, they found inclusions of remnants that come from blood vessels, and they suggested that dentin grew rapidly that vessels blood were included inside. In patients with OI, staining is more pronounced in the primary dentition. In the permanent dentition, these stains are not uniformly distributed, and the mandibular incisors and the first molars are the most affected than the other teeth. O'Connell and Marini have shown that dental color does not serve as a predictable index of tooth fragility with the exception of primary dentition, or they found that a yellow-

brown tone is associated with increased incidence of severe attrition and fractures of the enamel (Glorieux, 1998).

Spontaneous dental fractures and loss of enamel: Dentin around the pulp (circumpulphalic dentin) is more fragile than the subjacent enamel, this results in spontaneous fractures of the entire tooth (Glorieux et al., 1998) Indeed, one of the clinical features of the DI is the gradual disappearance of the enamel that covers the crown. Indeed, dentin, hypo mineralized, can not properly support the enamel that is easily detached from the tooth. Numerous plaques of uncoated dentin are then observed. At an advanced stage, there is no more enamel on the dentin which is then worn more quickly under the action of the masticatory forces (Glorieux, 2007).

Anomalies of shape and size: Radiographically, the crowns are prominent, the roots are usually narrower than normal, separated from globular crowns by a very pronounced constriction. The dental pulp is completely obliterated by dentin at the crown; at the root level, it is reduced to a thin thread of connective tissue. There is a gradual decrease in the crown height which brings the upper and lower gums closer together (Glorieux, 2007).

Malocclusions: Severe types of OI are usually associated with malocclusions due to craniofacial abnormalities. According to a case report, Class III malocclusions result in 70% -80% of cases of Type III and Type IV OI, with a high incidence of inverted articulations and anterior and posterior open bite (Glorieux, 2003). Appropriate occlusal development and tooth interdigitation depend on the growth and normal development of craniofacial mass and dentoalveolar complex that houses the dentition. In OI, the alteration of normal bone modeling and remodeling via the modest activity of osteoblast osteoclasts has a profound impact on patient occlusion. Occlusal malocclusions are described and divided into three major classes according to the sagittal relationship of the first permanent premolar. This classification has been expanded to describe the antero-posterior relationship between the maxillary and mandible related to the cranial base. Class I occlusion is normally considered as a normal spatial arrangement between the maxillary and mandibular bone bases. The majority of the population almost 70% present this type of occlusion. -The class II malocclusion, the second most common form of occlusion, is characterized by a displacement shift of the mandible in retrognathia compared to the maxillary and the cranial base, this malocclusion affects more than 20 to 25% of the population. The last and less numerous malocclusions in the population is that of class III is described as the location of the mandibular advanced in relation to the jawbone in the anterior-posterior dimension. This form can be caused by retraction of the maxillary sagittally in relation to the mandible, or by hypoplasia or maxillary deficiency, or by mandibular overdevelopment (prognathia) or by a combination of effects on both maxillae. This malocclusion is by far the least common and affects 1 to 3% of the Caucasian population. The percentage of individuals affected in any population varies by ethnicity, to some degree, it reflects the strong genetic relativity that influences many cases of Class III malocclusion compared to other types of malocclusion (Glorieux, 1998)

Medical care of patients with osteogenesis imperfecta: The multidisciplinary medical care of osteogenesis imperfecta (OI) is necessary given the number and difficulty of the problems

encountered, whether medical, surgical, rehabilitative, psychological, educational and social (Grond-Ginsbach, 2009).

Medication treatments

Bisphosphonates: Since the first Glorieux study in 1998, the antiresorptive treatment of OI with bisphosphonates (BP) has become the only pharmacological therapeutic option for moderate to severe OI, although randomized controlled trials demonstrating its efficacy are still poorly to this day. BPs are analogues of pyrophosphates, whose POP binding is replaced by a PCP link. The most recent BPs, which have a nitrogen atom in a side chain, such as pamidronate, neridronate, risedronate or zoledronate, inhibit the metabolic pathway of mevalonate; this results in a decrease in bone resorption through a reduction in osteoclastic activity and increased osteoclastic apoptosis.

In the context of OI, the effectiveness of a drug treatment should be measured using the following parameters:

- Bone mass
- Longitudinal growth
- Quality of life
- Incidence of fractures
- Prevention of the appearance of long bone deformities
- Progression of scoliotic deformities.

To this day, the literature reports nine randomized or "quasi-randomized" studies comparing oral or intravenous (IV) BP treatment with placebo or no treatment, and oral BPs. with BP IV Until now, only an increase in vertebral bone mass has been demonstrated in BP patients, so observational studies with or without historical control are mainly used to describe the clinical efficacy of these substances. The effect of BP on the stability of long bones is controversial, on the one hand, they cause an increase in cortical thickness without altering the trabecular thickness, which has a negative influence on the geometric variables of stability bon. X-ray analysis of the long bones and spine shows an increase in cortical thickness and much improved mineralization. During the treatment, we observe on X-rays the appearance of dense metaphyseal lines signifying each treatment. These dense spaced lines demonstrate that growth continues well during treatment. Controlled studies have corroborated these results, confirming in particular an increase in bone mineral content and a decrease in fracture rate. At present, we still do not know if treatment with BP can prevent long bone deformities or slow the progression of scoliosis. Growth, which is regularly monitored, is normal and depends on pubertal age. The size of children with a severe form, however, remains well below average (Bonaféa et al., 2013). In general, BPs are well tolerated, but they can be accompanied by a series of side effects that are not completely risk-free; in addition, the long-term effects on bone remodeling have not yet been sufficiently studied.

Growth hormones: The use of Growth Hormone GH in combination with Bisphosphonates has potential interest in osteogenesis imperfecta (OI). Stunting is a cardinal manifestation of OI. Although stunting may be variable within each of the forms of OI, there is a general relationship between severity and prognosis of size. Moderate forms of type I are responsible in some cases for significant delay below the 5th percentile of standard curves.

The interest of GH treatment in OI can actually be discussed in the context of stature growth but also its effect on the bone. GH mobilizes in particular IGF-I and IGFBP-3, which are important actors in osteogenesis. However, on this last point, the real impact of GH treatment in adults and children was discussed. Treatment with GH has long been considered in the OI (see Rauch and Glorieux). GH treatment has an effect on growth rate and, at least in some studies, on bone mineral density. Some studies suggest that treatment speeds up the growth rate in some patients. The recent study by Marini et al. shows a positive effect of GH on growth and bone mineral density (BMD) in some patients with Type IV OI, that recruits most subjects who responded positively to GH. The response to GH is lower in subjects with Type III OI. In this study, GH has a positive effect on bone remodeling (raise of PICP control of collagen synthesis) and histologically an increase in trabecular volume (Gajko-Galicka Anna, 2002).

Calcium and vitamin D: Calcium is essential for the development and maintenance of bone mass. The role of Vitamin D is to help the intestinal absorption of Calcium and to allow the mineralization of the bone matrix. We know the "key periods" where high intakes of calcium and vitamin D are essential: in childhood or adolescence, at the time when the framework is formed and where is constituted bone capital; after the menopause where the needs increase due to an acceleration of the bone remodeling, secondary to the hormonal deficiency, and beyond 65 years of age due to a decrease of the digestive absorption and food intakes often insufficient and a less solar exposure. Current treatments for osteogenesis imperfecta in adults stem from a good knowledge of their mechanism of action and proven efficacy in a number of osteopeniant bone diseases. Too often immobilized and protected from the outside environment, both children and adults with OI are easily deficient in vitamin D and calcium. Prevention of vitamin-calcium deficiency is therefore particularly necessary, using doses of the order of 500 mg to 1000 mg of calcium and 400 to 800 IU of vitamin D per day (Hata, 1988). Most studies conducted on the value of calcium intake to prevent bone loss and its fracture consequences show a slowing of bone loss proportional to calcium intake. In combination with Vitamin D (4), it reduces the risk of hip fracture in institutionalized patients over 75 years of age receiving 1g Calcium and 800 IU vitamin D daily versus placebo. The benefit is more pronounced in the most deficient women (39% of healthy women over 75 years are deficient in Vit D) and often the oldest in whom the secondary hyperparathyroidism is corrected. hyper remodeling (Hyper resorption). All current treatment regimens and all studies conducted in osteoporosis include calcium supplementation (500 to 1000 mg) and vitamin D (400 to 800 IU) adapted to the needs. They have a role of adjuvants (Aubry, 2004)

Analgesics: The different treatments for bone can not forget the relief of very common pain in patients with OI. The pain of bone origin respond well to treatment with bisphosphonates. The other pains can be the consequence of the deformations and the degenerative attacks also frequent. They are relieved by symptomatic treatment whose effectiveness does not differ from that obtained in patients without the disease (Hata, 1988).

The fracture pain is most often intense or very intense. The only appropriate drug treatment in this case is morphine. Fractures always occur unpredictably; the prescription must be anticipated, written; the family must have the drugs available at all times and know how to administer them.

Morphine oral can and should be given by the entourage at the place of the accident and before any mobilization or transfer. An important teaching time for families and children was made for 29 children, 7 of whom used morphine under these conditions, successfully (significant decrease in pain). Morphine is prescribed at a dose of 0.5 mg / kg in loading dose (maximum 20 mg), followed by doses of 0.2 mg / kg / 4h if necessary for the duration of the pain. Depending on the weight and age of the child, this intake will be in the form of capsules to open or swallow, tablets or oral solution. Teaching families includes the usual data on morphine (dosage, how to adjust doses. This time of information, training must address fears about this drug: side effects, drug addiction. These interviews also allowed children to express for the first time their "panic" fear of the following fracture and the pain it causes. As a result of these interviews, if the child and his family agree and understand the use of these medications, a prescription is given to them, as well as a booklet on the use of morphine. Ideally, other even more efficient proceedings could be carried out before the medical transport of these children, such as a locoregional anesthesia, a gesture practicable by the emergency medical services but rarely realized at present. If no medical pain really has any justification for being respected, the iatrogenic pain even more than the others, should be given the maximum attention of the caregivers (Glorieux, 2007).

Medical care of dentinogenesis imperfecta

Preventive treatment: Early identification and anticipated preventive interventions are critical factors for patients with OI to avoid the negative social and functional consequences of this disease. A regular periodic examination is imperative to identify any need for treatment of the initial dental lesions as soon as they occur. Meticulous oral hygiene, scaling, and oral rinsing can improve periodontal health. The application of fluoride and desensitizing agents help to eliminate tooth sensitivity in DI (Koo, 1995).

Curative treatment: Routine restorative techniques can often successfully treat mild to moderate DI forms. These treatments are commonly applied to permanent teeth as this dentition is less severely affected than the primary dentition. In the most severe cases with frequent fractures of the enamel and rapid dental wear, the treatment of choice is restoration by total coverage in both primary and permanent dentitions. The success of total covers is greater in teeth with crowns and roots' size and form that are near to the normal shape, which minimizes the risk of cervical fracture. In the case of severe losses of coronary structures and disruption of the vertical dimension, treatment with over-teeth can be considered. Removable dental prostheses on the teeth that are covered by fluoride-releasing glass ionomer cement have proven their effectiveness (Koo, 1995).

Aesthetic treatments: Teeth whitening has been reported to be helpful in brightening the color of teeth with dentinogenesis imperfecta with some success, but because of discoloration that is induced mainly by the yellowish brown underlying dentin, whitening only is certainly not able to restore the normal appearance of the tooth especially in cases with significant discoloration. The different types of veneers can be used to improve the aesthetics and to mask the greyish blue opalescence of the anterior teeth (Koo, 1995).

Orthognathy and orthodontics: As previously described, patients with OI (especially types III and IV) often have a less developed maxilla than the mandible. In some cases, the development of both jaws makes it difficult, if not impossible, to bring the teeth into a normal relationship even after orthodontic treatment. If the malocclusion is due to a growth problem, a combination of orthodontic appliance and orthopedic surgery can provide dental alignment. The orthodontic appliance period is also shown to be useful after surgery. Some reports published about these surgeries indicate the good postoperative healing of the maxillae.

The constraints of bleeding problems and the response to general anesthesia in patients with OI are needed during OI surgeries. In addition, the recent use of Bisphosphonates to treat various bone disorders triggers additional questions about maxillary surgeries. The most important restrictive factor limiting tooth movement is the condition of the underlying bone.

However, the orthodontic movements applied to the teeth are expected to be clearly slowed down because of the decrease in bone resorption due to the use of bisphosphonates.

Patients with OI type I may benefit from orthodontic treatment as long as the response to force application therapy in these patients is similar to the normal population. Type III and Type IV of the OI present more complicated difficulties. In fact, their craniofacial deformities are more pronounced, especially the class III malocclusions with open bite seen in the majority of these patients. The elimination of the open spaces will bring a big benefit to the patients by the restoration of the masticatory and phonatory functions.

Psychosocial care of patients: Psychological care within the context of the OI is a very important aspect of the therapeutic approach but is often neglected. In the case of children with OI, parents and fraternity, as well as the child experience a traumatic experience that imposes the need for continuous support by professionals. For a child, it is also important to consider the psycho-social aspects in the different stages of development during childhood and adolescence. A comprehensive plan to assist the transition to adulthood is considered a key aspect of the medical care of this disease. Community-based support groups and companies can provide additional support for patients and their families and can be a useful adjunct to medical care (Kuslich, 2003)

Presentation of clinical cases : Medical Care in the Dental Consultation and Treatment Center of Casablanca

It is about :

- Women, 33 years old
- Skeletal deformation
- Followed-up in the Traumatology service for Osteogenesis Imperfecta
- Treated for 3 years by injectable Bisphosphonates (1 inj / year)
- Reason for consultation: Pain in the right upper premolar sector.

Clinical Examination

- Shrunken palate and ogival, hypertrophy of ridges
- Presence of bone denudation at the sector 24/25




Fig. 1. Presentation of the patient

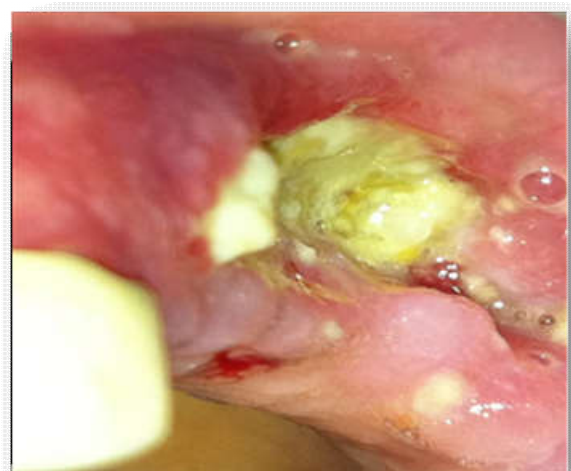
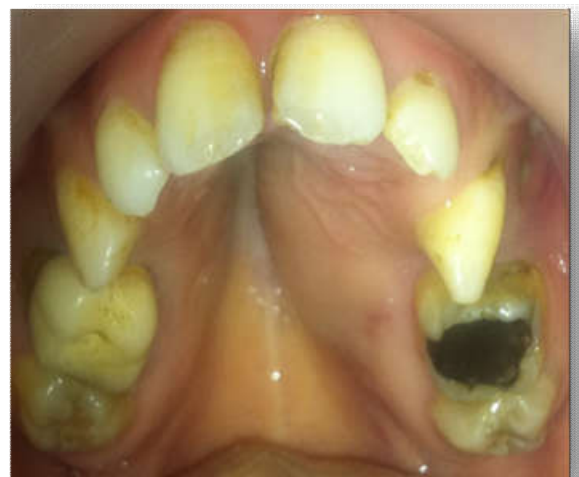
Fig. 2. (a-b): Endo buccal examination

- Appearance 3 months ago after extraction of the 25 in a quack.
- Mixed radiological imaging.
- Partial rupture of the external cortex
- Agenesis of the sinuses.

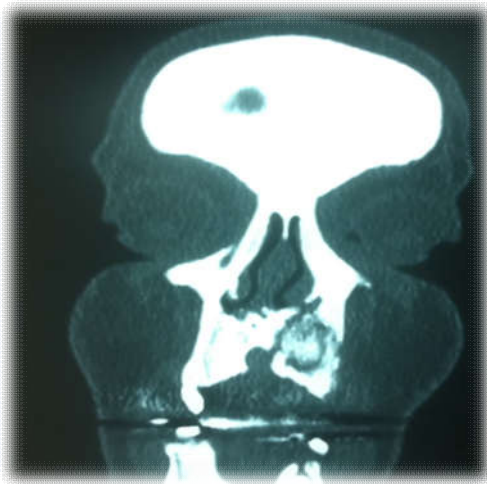
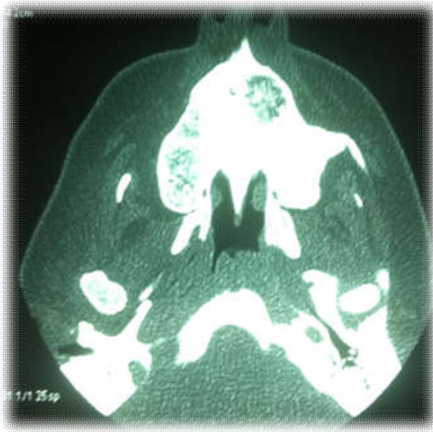

Fig. 3 (a-b). Radiological Examination (TDM)

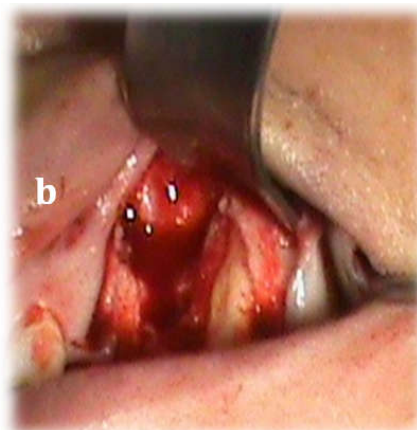
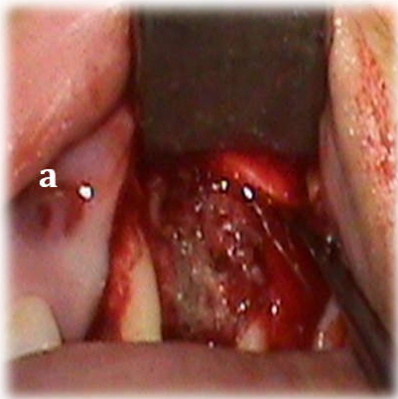


Fig 4 (a-b). Curettage of osteitis

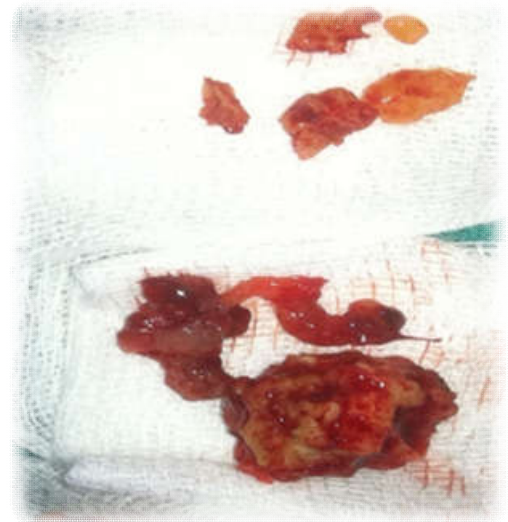


Fig. 5. Bone Sequestrum

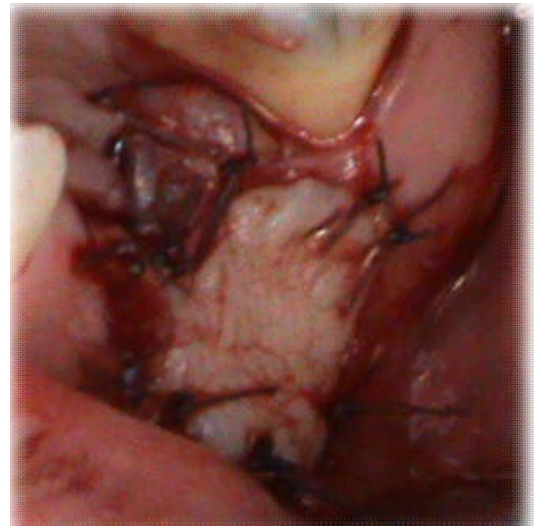


Fig. 6. Connective tissue graft

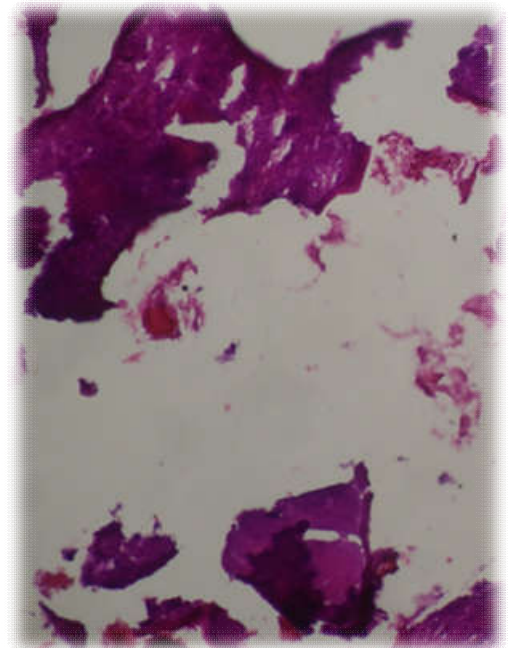


Fig. 7. Anatomico-pathological examination

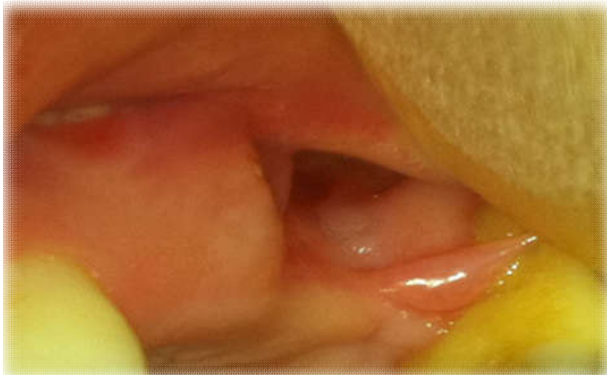

Fig. 8. Check after 10 months

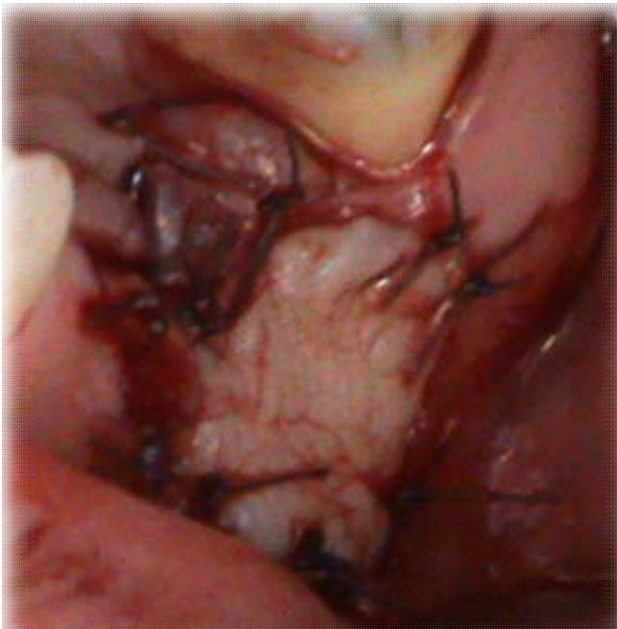
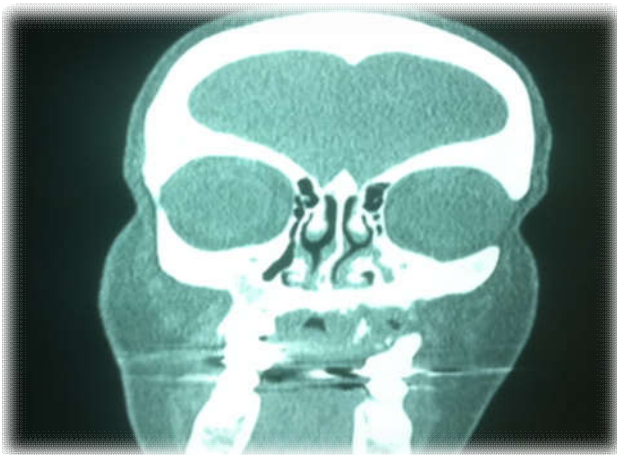

Fig. 9. Frontal cranio-facial TDM section after 10 months

Cranio-facial frontal Section

Cranio-facial Axial Section

Medical Care

Medical Treatment

- Amoxicillin 1g: 2 tb / day
- Metronidazole 500 mg: 1tb 3/day

- Chlorhexidine: oral rinse 3/day
- Curettage of the osteitis focus with local anesthesia
- Closing of the residual cavity by a conjunctive graft.

Anatomopathology: Actinomycotic osteitis.

DISCUSSION

Osteogenesis imperfecta

- Hereditary bone dysplasia
 - Bone fragility
 - Skeletal deformities
 - Growth deficiency
- Treatment of choice: Bisphosphonates
 - Most serious side effects: bone necrosis
 - Specific care protocol / regular follow-up.

Conclusion

Osteogenesis imperfecta is a genetic disease that includes a group of affections of variable severity all characterized by bone fragility. It associates skeletal signs of variable severity mainly fractures, ligamentous hyperlaxity, dentinogenesis imperfecta and bone deformities, and inconstant extra skeletal signs such as blue sclerotic, deafness and vascular fragility. Its classification has recently been completed both clinically and histomorphometrically. There is great variability of expression with major lethal perinatal forms and moderate forms that may go unnoticed. It is a disease usually due to an abnormality in the production of collagen which is the main fibrous protein of bone and teeth. The majority of cases are transmitted in an autosomal dominant mode, associated with a mutation in the COL1A1 or COL1A2 genes, but in other cases the autosomal transmission is recessive. Today advances in the fields of genetic and therapeutic knowledge of the OI give us the opportunity to establish multidisciplinary care increasingly guided by the genotype in a personalized way. The evaluation of medical treatments, currently in progress, gives hope for the end of a harmful empiricism. The bisphosphonates associated with surgery are probably changing the long-term outcome of the disease. They marginalize other therapeutic attempts such as hematopoietic marrow transplants that remain poorly evaluated and highly questionable ethically. In this context, gene therapy is a very distant and uncertain hope.

REFERENCES

- Ackerman JL., Proffit WR. 1969. The characteristics of malocclusion: a modern approach to classification and diagnosis. *Am J Orthod.*, 56 (5) : 443.
- American Academy of Pediatric Dentistry. 2013. Guideline on Dental Management of Heritable Dental Developmental Anomalies, 2013, 36 (6) : 14-15.
- Aubry MC. 2004. Obstétrique et femme : Imagerie foetale chez une mère. *J. Assoc. Ostéogénèse Imparfait N° 50 spécial.*
- Barsh GS., Byers PH. 1981. Reduced secretion of structurally abnormal type I procollagen in a form of osteogenesis imperfecta. *Proc Natl Acad Sci USA*, 78:5142-5146.
- Bonaféa L., Giuntab C., Haslerd C., Jannerf M., Kränzline M., Linkb B., Meiere C., Ramseierb LE., Rohrbachb M.,

- Ungera S. 2013. Ostéogénèse imparfaite: manifestations cliniques, diagnostic et prise en charge de l'enfance à l'âge adulte. *Forum Med Suisse*, 13(46) : 925-931.
- Doyle SA., Smith BD. 1998. Role of the pro- α (I) COOH-terminal region in assembly of type I collagen: Disruption of two intramolecular disulfide bonds in pro- α 2(I) blocks assembly of type I collagen. *J Cell Biochem.*, 71:233-242.
- Emrich RE., Brodie AG., Blayney J. 1965. Prevalence of Class I, Class II, and Class III malocclusions (angle) in an urban population. An epidemiological study. *J Dent Res.*, 44 (5) : 947-53.
- Gajko-Galicka Anna. 2002. Mutations in type I collagen genes resulting in osteogenesis Imperfecta in humans Vol. 49 No.
- Glorieux FH. 2007. Guide to Osteogenesis Imperfecta for Pediatricians and Family Practice Physicians National Institutes of Health
- Glorieux FH., Bishop NJ., Plotkin H., Chabot G., Lanoue G., Travers R. 1998. Cyclic administration of pamidronate in children with severe osteogenesis imperfecta. *New England J. Med.*, 339:947-952
- Glorieux FH., Pettifor JM., Jüpnér H. 2003. Pediatric Bone: Biology and Diseases. San Diego: Academic Press. p. 401-63.
- Grond-Ginsbach C., Debette S. 2009. The association of connective tissue disorders with cervical artery dissections. *Curr Mol Med.*, 9: 210-214.
- Hata R., Kurata S., Shinkai H. 1988. Existence of malfunctioning pro α 2 (I) collagen genes in a patient with a pro α 2 (I)-chain-defective variant of Ehlers- Danlos syndrome. *Eur J Biochem*, 174:231-237.
- Koo WWK., Walters, Bush AJ. 1995. Technical considerations of dual energy X-ray absorptiometry-based bone mineral measurements for pediatric studies. *J Bone Miner Res.*, 10: 1998-2004.
- Kuslich C., Byers PH. 2003. Exon-Skipping Mutations that Result in OI Type IV. *Connective Tissue and Its Heritable Disorders: Molecular, Genetic, and Medical Aspects*. Edit Apr 14.
- Lindau B., Dietz W., Lundgren T., Storhaug K., Noren JG. 1999. Discrimination of morphological findings in dentine from osteogenesis imperfecta patients using combinations of polarized light microscopy, microradiography and scanning electron microscopy. *Int J Paediatr Dent.*, 9(4):253-61.
